

# LASER TREATMENT of Oral PIGMENTATION

## Oral

mucosa is normally pink, although the colour varies depending on the location, function and underlying tissue; under both physiologic and pathologic conditions. The final color of the oral mucosa is determined by the accumulated materials on the epithelial surface, thickness of the keratin layer or epithelium, numbers and melanogenic activity of the melanocytes, the vasculature and the composition of the sub mucosal tissues [1]. Pigmented lesions are commonly found in the mouth. Such lesions represent a variety of clinical entities, ranging from physiologic changes (e.g., racial pigmentation) to manifestations of systemic illnesses (e.g., Addison's disease) and malignant neoplasms (e.g., melanoma and Kaposi's sarcoma).


Oral pigmentation may be exogenous or endogenous in origin. Exogenous pigmentation is commonly due to foreign-body implantation in the oral mucosa. Endogenous pigments include melanin, haemoglobin, haemosiderin and carotene. Melanin is produced by melanocytes in the basal layer of the epithelium and is transferred to adjacent keratinocytes via membrane-bound organelles called melanosomes. Melanin is also synthesized by nevus cells, which are derived from the neural crest and are found in the skin and mucosa. Pigmented lesions caused by increased melanin deposition may be brown, blue, grey or black, depending on the amount and location of melanin in the tissues. [2]

### Physiologic (Racial) Gingival Pigmentation

In dark-skinned races, the presence of a black-brownish border along the attached gingiva can usually be appreciated.

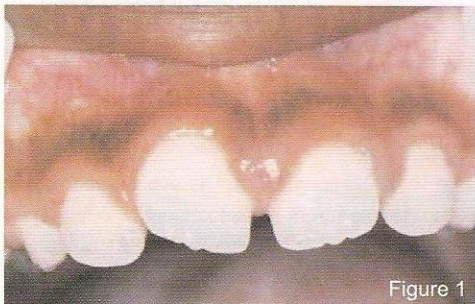

Figure 1: Physiologic (racial) pigmentation in an Indian boy presenting as a well-demarcated dark brown band on the attached gingiva. The marginal gingiva is unaffected.



Dr. Uddhav A. Patil, MS, Mch (Plast. Surg.), MACP (Phlebology) LakshyaKiran Lasers, Kolhapur, India

### Smoker's Melanosis

Smoking may cause oral pigmentation in light-skinned individuals and accentuate the pigmentation of dark skinned patients [3]. There is increased production of melanin, which may provide a biologic defence against the noxious agents present in tobacco smoke. Smoker's melanosis occurs in up to 21.5% of smokers [4]. The intensity of the pigmentation is related to the duration and amount of smoking [4,5]. Women are more commonly affected than men, which suggests a possible synergistic effect between the female sex hormones and smoking [4]. The brown-black lesions most often involve the anterior labial gingiva, followed by the buccal mucosa and lips (Fig. 2). Smoker's melanosis usually disappears within 3 years of smoking cessation.

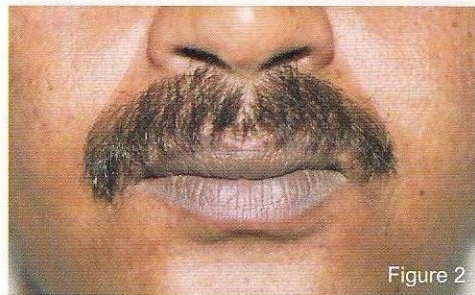


Figure 2: Smoker's Melanosis affecting entire lip mucosa in a 41 year old cigarette chain smoker.

In addition to the complexity of multiple etiologic factors, various stimuli can evoke the same tissue response and different conditions might share the same histopathologic features. The color

and shape of the lesions in the same disease varies according to the location and duration of the lesions [6] (Fig. 3). For these reasons, the differential diagnosis of pigmented lesions in the oral mucosa is sometimes difficult.

In general, benign pigmented lesions show regular borders and are small, symmetric and uniform in colour. They may be either flat or slightly elevated. In contrast, irregular borders, colour variation, and surface ulceration suggest malignancy. Therefore, an understanding of the cause of mucosal pigmentation and appropriate evaluation of the patient are essential. Evaluation should include a full medical, dental and drug history as well as oral habits (such as smoking or betel nut chewing), thorough extra and intraoral examination and in some cases, biopsy and laboratory investigations.

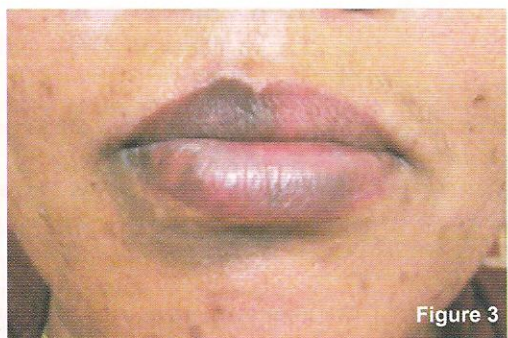

Figure 3: Asymmetrical distribution of pigment on both upper and lower lip mucosa extending on peri-oral skin in a female.

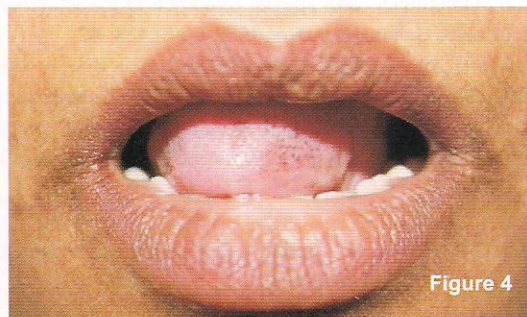


Figure 4: Speckled pigmentation over tip of the tongue and lip commissures in a female of 28 year.

### Material & Methods

Here we present our experience of treating familial and physiologic pigmentation of tongue, gums and lips with 1064 nm Q-Switched laser (Q-Plus B, Quanta Systems, Italy, distributed by APCL Medico). Out of ten cases, eight were young females in premarital age group between 21 to 28 years. Three patients had speckled pigmentation over the tip (Fig. 4), borders (Fig. 5A, 5B) as well as the under surface of the tongue. Three had it on gums and lips while another three had it only on lips. One 41 year old male had smoker's melanosis over gums as well as lips but took treatment on lips only, making lips as the commonest site for treatment in 8 out of 10 cases.

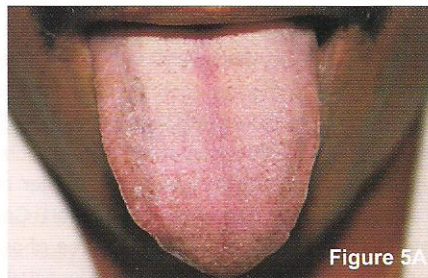


Figure 5A: Pigmentation of the tongue border in a 34 year old non smoker male

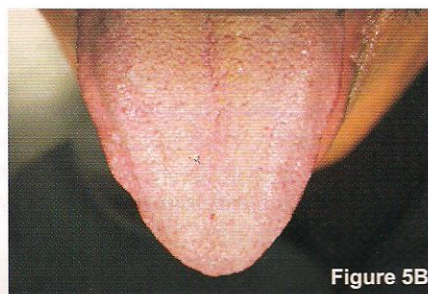


Figure 5B: Complete clearance after 8 sessions of Q-Switched laser treatment.

We always used the smallest i.e. 2.5 mm spot size as the pigment is superficially located in epithelium. For lips local anaesthetic cream containing a combination of lidocaine 2.5% and prilocaine 2.5% was applied once or twice approx. 45 mins. to 1½ hour prior to the laser procedure. For tongue and the gums ice cube sucking just prior and during the treatment was used as a method of numbing the area. Just greying or very light frosting was the treatment end point in case of lips and gums while in case of tongue it was extended to occasional pin point bleed (Fig. 6A, 6B).

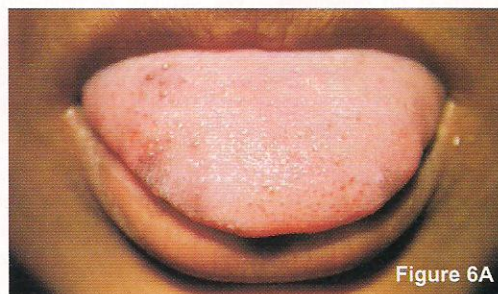


Figure 6A: Patchy pigmentation of the tongue in a 21 year old girl.

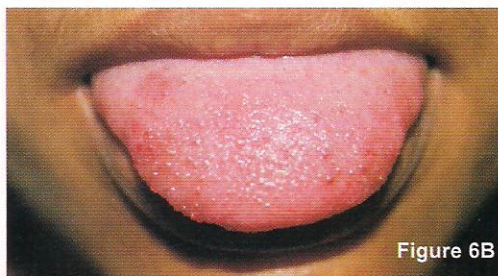


Figure 6B: Good clearance after 2nd session. Note pin point bleeding after 3rd session. She had complete clearance after 4th treatment.

A magnifying glass with illumination was used for accuracy and care was taken to avoid lasing the normal pink mucosa at the borders of the lesion. Tongue being highly muscular, while treating it needed stabilization by the operator's finger pinch. Post treatment immediate ice cooling for comfort and later regular application of a moisturizing lip balm along with an oral B Complex preparation was sufficient. Mild to moderate degree of oedema appears immediately after the treatment and lasts for a day or two (Fig. 7).

The average starting energy was 7 J/cm<sup>2</sup>. On an average increment of 5% was required during the subsequent treatments to continue getting clearance even though the increment ranged from 3.3% to 20% depending on starting energy, tolerance of mucosa, pain tolerance of the patient and the end point achieved. Invariably all patients got some clearance with each treatment and an average of 50% clearance was achieved after 3rd treatment. Maximum number of treatments required was eight. There were no side effects. The improvement or clearance achieved has remained persistent over the maximum period of follow up i.e. 1 year except in one case of lip pigmentation who had some recurrence after 3rd treatment.

### Conclusion :

Even though intraoral pigmentation remains hidden for most of the time, the patient may look at it as a blemish and desire to get rid of it. The pigmented gums and lips definitely decrease the smile value of the person. There are no satisfactory surgical procedures for these conditions. After establishing the diagnosis of oral pigmentation, laser treatment with 1064 nm Q-Switched laser is found to give consistently good and long lasting results with no side effects. Treatment acceptance is good as they are very well tolerated and there is almost no downtime. We strongly recommend this modality for the given indications.

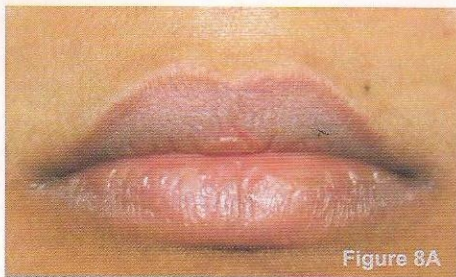


Figure 8A: Familial lip pigmentation in a 24 yr. girl.

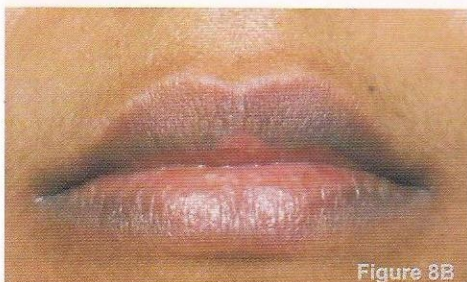


Figure 8B: Excellent clearance after 3rd laser treatment.

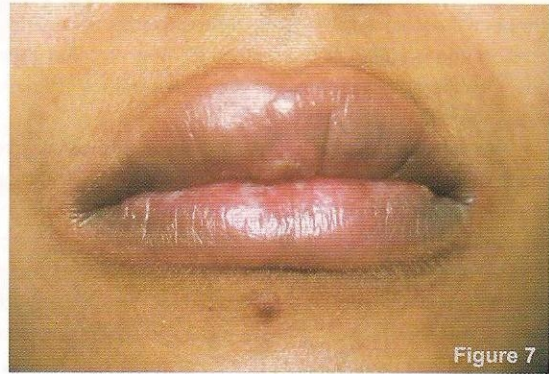


Figure 7: Post laser Oedema, no breakdown or pin point bleeding.

### References

1. Dummett CO, Barends G. Pigmentation of the oral tissues: a review of the literature. *J Periodontol.* 1967;38:369-378.
2. R. Kauzman A, Pavone M, Blanas N, Bradley G. Pigmented lesions of the oral cavity: review, differential diagnosis, and case presentations. *J Can Dent Assoc.* 2004;70(10):682-3.
3. Hedin CA, Axell T. Oral melanin pigmentation in 467 Thai and Malaysian people with special emphasis on smoker's melanosis. *J Oral Pathol Med* 1991; 20(1):8-12.
4. Axell T, Hedin CA. Epidemiologic study of excessive oral melanin pigmentation with special reference to the influence of tobacco habits. *Scand J Dent Res* 1982; 90(6):434-42.
5. Araki S, Murata K, Ushio K, Sakai R. Dose-response relationship between tobacco consumption and melanin pigmentation in the attached gingiva. *Arch Environ Health* 1983; 38(6):375-8.
6. Gaeta GM, Satriano RA, Baroni A. Oral pigmented lesions. *Clin Dermatol.* 2002;20(3):286-8.